



Science, Movement and Health, Vol. XXII, ISSUE 2, 2022
June 2022, 22 (2): 155 - 164
Original article

Descriptive and functional evaluation data of the sprained knee

ROȘU Bogdan¹, CORDUN Mariana¹

Abstract

Aim. Patients with knee injuries may be consulted in a first stage by specialists, such as the sports doctor, and in a second stage, depending on the severity of the injury and the therapeutic orientation, it may be necessary to consult an orthopedic surgeon and / or medical rehabilitation.

Methods. Particularly important in the traumatic pathology of the knee is the clinical examination. It must be rigorous and systematic because, based on it, a correct diagnosis can be established, which also assesses the severity of the lesions. Only in this way can the optimal therapeutic decision be made in order to establish an accurate initial diagnosis and to evaluate the severity of the sprain, depending on which medical or orthopedic-surgical treatment is decided.

Results all the listed elements will allow us to establish the therapeutic management in the recent sprain of the knee and to differentiate the affected structures: sprain with the interest of the collateral ligaments or with the damage of the central pivot, represented by the cruciate ligaments.

Conclusion- Knee injuries, most often secondary to a sports, domestic or road accident, are one of the main causes of medical consultation.

In sports, the most common injuries to the lower limbs cover various clinical pictures, from common contusion, tendonitis, bursitis, periostitis, sprain, muscle rupture, meniscal rupture, to severe pathologies such as ligament rupture, chondropathy and fractures. All of these clinical situations can have multiple causes, from inadequate equipment or terrain, poor heating, psycho-physical overload, and trauma ignored in the past.

Keywords: knee movements, mobility, amplitudes, stability.

Introduction

The basic movements of the knee joint are those of flexion and extension, and their amplitude is measured from the reference position established by certain landmarks.

Starting from the anatomical position, a movement that brings the posterior faces of the leg and thigh closer is called leg flexion. During active flexion, the flexor muscles contract and form a mass, posterior to the calf and thigh bones, and limit flexion. Passive flexion is wider (the flexor muscles are stretched and allow compression) (Higgins et al., 2007).

The active flexion reaches an amplitude of 140° if the hip is already flexed and only 120° if the hip is extended. This difference is due to the fact that the knee tendons lose some of the efficiency with the extension of the hip. If the tendons contract suddenly and strongly, the knee is projected in flexion, and the end of the active extension is followed by a degree of passive extension.

Passive knee flexion reaches an amplitude of 160°. During knee flexion, the femur-tibial joint rotates and slides the femoral condyles on the tibial plateau (Siegel et al., 2012).

These two components are necessary to achieve a large flexion and to increase the amplitude by default, without posterior dislocation of the femoral condyles. The run takes place at the beginning of the flexion and is pure up to 15°. Then, gradually, the slip will appear (by tensioning the central pivot) and, finally, the rolling will start, when the movement continues over 120° (Ayeni, 2012).

The knee allows flexion and extension around a virtual transverse axis, as well as a slight medial and lateral rotation around the lower axis in the flexed position. The knee joint is called mobile because the menisci move over the tibia during rotation, while the femur rolls and slides on both menisci during extension flexion (Dwyer and Whelan, 2012).

The center of the transverse axis of the extension-flexion movements is located where the collateral ligaments and the cruciate ligaments intersect. This center moves up and back during flexion, while the distance between the center and the articular surfaces of the femur changes dynamically with the decreasing curvature of the femoral condyles. The total stroke is dependent on several parameters, such as soft tissue restrictions.

Extended knee position: both the lateral and medial collateral ligaments and the anterior part of the anterior cruciate ligament are stretched. During extension, the femoral condyles slide and roll into a position that causes the tibial collateral ligament to fully stretch. During the last 10° extension, a mandatory terminal rotation is triggered in which the knee is rotated medially by 5°. The final rotation is produced by a lateral rotation of the tibia in the weightless limb and a medial rotation of the femur in the weight-bearing limb. This terminal rotation is possible by the shape of the medial femoral condyle, assisted by contraction of the popliteal muscle and is caused by the stretching of the anterior cruciate ligament (Siegel et al., 2012).

¹ National University of Physical Education and Sports, Faculty of Physical Education and Sport, Bucharest, Romania
Email: rosubogdan81@yahoo.com

Flexed position: the collateral ligaments are relaxed, while the cruciate ligaments are stretched. The rotation is controlled by the cruciate ligaments. The two ligaments twist around each other during the medial rotation of the tibia which reduces the possible rotation, while they become improper during the lateral rotation of the tibia. Due to the oblique position of the cruciate ligaments, at least part of one of them is always tense, these ligaments controlling the joint, because the collateral ligaments are relaxed (Bell, 2015).

Viewed in the sagittal plane, the articulated surface of the femur is convex, while the tibia is concave.

Open kinetic chain: during knee extension, the tibia slides anteriorly to the femur. Specifically, from knee flexion to full extension, the tibia rotates externally. During knee flexion, the tibia slides posteriorly to the femur and from the full extension of the knee, it rotates internally on the tibia.

Closed kinetic chain: during knee extension, the femur slides posteriorly to the tibia. From knee flexion to full extension, the femur rotates internally on the tibia. During knee flexion, the femur slides anteriorly to the tibia and from the full extension of the knee to complete flexion, the femur rotates externally to the tibia.

In flexion, the condyle slides and retracts while in extension, the condyle slides and advances.

During axial rotation, anteroposterior movements of the femoral condyles occur on the tibial plateau.

In the external rotation, the external femoral condyles advance into the external glenoid, while the internal femoral condyles retract into the internal glenoid and vice versa into the internal rotation (Nakamura et al., 2011).

It should be noted that the movement of the external femoral condyles is greater than that of the internal femoral condyles. This phenomenon is related to the anatomy of the internal and external tibial plateau and the position of the center of rotation of the knee.

Joint mobility. The knee is the intermediate joint of the lower limbs, located between the hip and the ankle. It is the largest superficial joint. It belongs to the group of synovial joints. The knee actually consists of two joints at the junction of three bones, the femur, tibia and fibula: the femur-tibial joint and the patellofemoral joint (Relph et al., 2013).

The knee allows you to maintain posture and achieve gait and therefore requires stability that must be combined with mobility. In order to preserve both imperatives, the anatomy of the joint consists of articular surfaces with low congruence to ensure

mobility and strong periarticular ligament-muscular elements to ensure the necessary stability (Marouane et al., 2015).

In the anatomical reference position, the knee has certain characteristics. In the sagittal plane: the angle formed between the femur and the tibia is 180° . In the frontal plane: there is a physiological valgus, the angle formed between the femur and the tibia being from 170° to 175° . Horizontally: the tibia is in an external rotation of 20° to the femur.

The active extension is almost zero. It is 5° to 10° in passive extension. When these limits are exceeded, we enter the pathological sphere, called the genu recurvatum.

Axial rotation is defined by the rotation of the foot around its longitudinal axis, when the knee has several degrees of flexion, because in extension the knee is in the locked position. For a knee bent at 90° , the active external rotation is 40° and 30° for the active internal rotation. In the passive, the amplitudes increase by 5° to 10° . In the last 20° of extension, there is a mandatory external rotation of about 14° , the so-called automatic rotation. This is due to the stretching of the anterior cruciate ligament during extension, but also to other ligament and muscle forces, menisci and joint surfaces, which are asymmetrical structures.

Femur - tibial joint. The tibiofemoral joint is of the trochlear type. The architecture of the articular surfaces favors flexion. The tibial plateaus are two in number, separated by an anteroposterior ridge. They are posterior concave. They are not symmetrical. The superior epiphysis of the tibia has two articular fossae (external and internal glenoid cavity) with a slightly convex shape and a small radius of curvature (Ahlden et al, 2012). The femoral condyles are convex with an anteroposterior decreasing radius. They are also asymmetrical.

During flexion, the femoral condyles roll over the tibial plateau and also slide. External condyles, due to structural differences, slide more than internal ones.

The external rotation of the tibia towards the femur leads to the advancement of the external condyle and the withdrawal of the internal condyle. Displacements are reversed during the internal rotation of the tibia. The following should be noted: the external condyles do not have the same displacement profile as the internal ones due to structural differences (Tourville et al., 2014).

Joint surfaces. The femoral joint surface consists of femoral condyles (figure 1) which are at the lower and posterior end of the femur. They describe a spiral whose radius of curvature decreases anteroposteriorly.

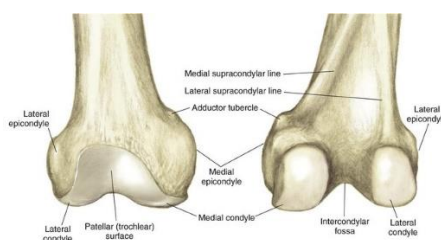


Figure 1. Femoral condyles (source- www.Orthobullets, knee, physical, exam.com)

The condyles are separated by the intercondylar fossa where the anterior and posterior cruciate ligaments are inserted. They are supported by the medial and lateral supracondylar tubercles to which the tendons of the gastrocnemius muscles attach (Suero et al., 2013).

The tibial joint surface consists of tibial fossae that are located on the upper surface of the proximal end of the tibia. The medial tibial fossa is oval and slightly concave, while the lateral fossa is rounded, smaller and slightly convex.

Between the two tibial fossae are the anterior and posterior intercondylar surfaces separated by the intercondylar eminence. This area allows the insertion

of the anterior and posterior cruciate ligaments and the menisci.

The *menisci* are arranged between the femoral condyles and the tibial plateaus (figure 2). These are complex crescent-shaped, triangular fibrocartilages, thicker at the periphery and thinner inward. One is medial, and has the shape of the letter C, the other lateral and has the shape of the letter O. The menisci are fixed by their horns, anterior and posterior, at the level of the tibial intercondylar surfaces, and their outer face adheres to the joint capsule.

The menisci join anteriorly to the transverse ligament of the knee.

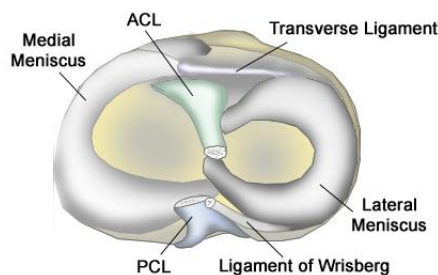


Figure 2. Menisci (source- www.Orthobullets, knee, physical, exam.com)

It should be noted that the medial meniscus is closely related to the collateral tibial ligament.

In the femur-tibial joint, the menisci make it possible to increase the contact surface and thus stabilize the joint, but also distribute the forces transmitted from the femur to the tibia. It also acts as a shock absorber and absorbs shocks. Finally, they improve lubrication through a better distribution of synovial fluid.

During the various movements of the knee, the external meniscus has a greater mobility than the internal one due to its areas of attachment, at the level of the anterior and posterior horn, which are closer. During flexion movements, both menisci are pushed posteriorly.

In rotational movements, the menisci move and deform. Thus, during the external rotation of the tibia, the external meniscus mobilizes anteriorly, while the internal meniscus is directed posteriorly; meniscus movements occur inversely during internal rotation.

Articular amplitudes

Flexion is the posterior movement of the leg in the sagittal plane and has an amplitude between 0° - 135°.

Factors that limit movement are the tension of the extensor muscles of the knee when the thigh is in

extension and the contact of the knuckle with the back of the thigh (Ingelsrud et al., 2014).

The *stabilization* of the movement is achieved by the contraction of the sacrolumbar muscles, the lumbar square and by the weight of the thigh and pelvis.

The main muscles are:

- the femoral biceps (long portion) with the origin on the postero-internal face of the sciatic tuberosity and with the insertion on the external face of the fibula head and on the external tuberosity of the tibia.

- the biceps femoris (short portion) originating along the entire length of the external ridge and on the upper part of the external supracondylar line and with the insertion on the external face of the fibula head and on the external tuberosity of the tibia.

- the semimembranosus originating on the supero-external part of the sciatic tuberosity and with the insertion on the horizontal groove, on the postero-internal face of the internal tuberosity of the tibia, on the internal lateral ligament of the knee and on the aponeurosis of the leg.

- the semitendinosus with the origin on the inferior and inner face of the sciatic tuberosity and with the insertion on the antero-internal face and on the upper part of the superior diaphysis.

The accessory muscles are: popliteal, tailor, internal law, twins.

The extension is the anterior movement of the leg in the sagittal plane and has an amplitude between 135 ° and 0 °.

Factors that limit movement are the tension of the popliteal oblique ligament and the cruciate and collateral ligaments of the knee, but also the tension of the flexor muscles of the knee.

The stabilization of the movement is achieved by the contraction of the abdominal muscles and the fixation of the anterior right, but also by the weight of the thigh and the pelvis.

The main muscles are:

- the anterior right originating on the spine and the antero-inferior iliac crest and the supracondylar groove and the insertion on the base of the patella.

- the crural with the origin on the antero-external face of the upper third of the femoral shaft and the insertion on the deep part of the femoral quadriceps tendon that is inserted on the base of the patella.

- the internal vastus with the origin on the lower half of the intertrochanteric line, the rough line and the proximal part of the internal supra-condylar ridge and the insertion on the inner edge of the patella and the femoral quadriceps tendon.

- the vastus external originating on the upper part of the intertrochanteric line, on the antero-inferior edge of the great trochanter and on the upper half of the rough line and the insertion on the outer edge of the patella, forming part of the femoral quadriceps tendon.

Femur - patellar joint. In the vertical direction, the patella (figure 3) is fixed between the patellar tendon and the quadriceps tendon, between them giving rise to an open angle at the outside, the only motor element acting on the patella being the quadriceps tendon which raises the patella and pulls it out.

In the transverse direction, the patella has two fins, one internal and one external. The inner fin is strengthened by the insertion of the internal vastus and the internal meniscus-patellar ligament, and the outer fin by the insertions of the external vastus, the fascia lata and the external meniscus-patellar ligament.

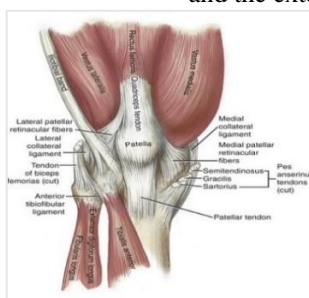


Figure 3. Patella (source- www.Orthobullets.com, knee, physical, exam.com)

A network is formed over the patella, which fixes the trochlea, the network being formed by the fibers of the vest, the tailor, the fascia lata, the aponeurosis of the leg and the right anterior. The role of the patella is to move the tendon of the quadriceps away from the trochlea in the maximum extension movement; thus, the lever arm increases by 50%.

The posterior surface of the patella is in contact with the anterior surface of the distal epiphysis of the femur. The patellar articular surface is divided by a vertical ridge in two facets, one median and one lateral (Kim et al., 2015).

The anterior aspect of the distal epiphysis of the femur, called the trochlea, consists of two facets, medial and lateral, separated by a vertical depression that allows a good interconnection with the patellar joint surface. The lateral face is wider and more prominent than the medial one.

The patella is attached laterally by different structures that fix it: the median and lateral patellar retina, the patella fins and the menisco-patellar fins. They previously protect the knee (Aminaka et al., 2008)

During flexion, the patella moves mainly vertically, in the frontal plane, downwards, in the trochlear neck and in the intercondylar fossa. In the other two planes,

the movements are small in amplitude and of minor importance.

The quadriceps exerts a significant force of baking the patella in the femoral trochlea, the greater the amplitude of flexion.

This force varies depending on the size of the previous displacement of the center of gravity of the body and compresses the patella less on the trochlea. In the physiological valgus, this force tends to remove the patella from the trochlea.

The patella increases the lever of the extensor mechanism of the knee (maximum between 20 ° and 40 ° flexion). It also makes it possible to reduce the stresses on the patellar ligament in particular, as the degree of flexion is important.

On the extended knee, the patella is placed upward because the contraction of the quadriceps pulls it up and out, so that it loses contact with the trochlea.

In flexion, a force is produced that strongly presses the patella on the femoral trochlea, this force appears at the bisector of the angle between the patellar tendon and the direction of action of the quadriceps.

The path formed by the patella is concave on the outside; at the beginning of the flexion it comes into contact 1/3 lower than the patella with the femoral trochlea, at 45 ° flexion the average 1/3 of the patella

comes into contact with the femoral trochlea, and at flexion greater than 60 ° the contact is established between the upper 1/3 patella and femoral trochlea; so the actual pressure is exerted only on 1/3 of the ball joint surface.

Stabilization of the patella is ensured by bone factors (prominence of the lateral and medial femoral condyle), muscular factors (vast medial, semimembranosus, semitendinosus, gracilis and popliteal), capsulo-ligamentary factors (patellar retinaculum), dynamic factors (internal traction of the patella during r internal).

Extra-capsular ligaments. Of the extracapsular ligaments, only the lateral, medial, and patellar ligaments are of clinical interest. The other extra-capsular ligaments are the arched popliteal ligament and the oblique popliteal ligament (Tardy et al., 2014).

The patellar ligament is a thick fibrous band that extends from the tip of the patella to the tibial tuberosity in the extension of the quadriceps femoral muscle tendon. The lateral fibular or external collateral part extends from the lateral epicondyle of the femur to the lateral face of the head of the fibula and is oriented obliquely downwards and backwards. It is separated from the lateral meniscus and the popliteal muscle tendon.

The lateral tibial ligament or internal collateral extends from the upper and posterior part of the medial epicondyle of the femur, obliquely downwards and forwards to the proximal extremity of the tibia. During movement, the deep fibers attach firmly to the medial meniscus. This anatomical feature makes it possible to understand that any sprain of the tibial collateral ligament causes injury to the medial meniscus.

The internal and external collateral ligaments ensure the lateral stability of the knee in extension. In flexion, they relax and thus allow the achievement of a certain degree of valgus or physiological varus.

The internal collateral ligament is in a position of fragility during forced valgus. Instead, the external collateral ligament is in a fragile position during a forced varus. Valgus or varus can be secondary to direct or indirect shock, which causes injury.

These ligaments are stretched in external rotation and relaxed in internal rotation.

The intracapsular ligaments are called the cruciate ligaments and connect the tibial femur. They are the central pivot of the knee and are extra-synovial (Eggl et al., 2015).

Their function is to ensure the antero-posterior stability of the knee and to maintain contact of the joint surfaces during flexion movements.

These ligaments are kept crossed in all movements and have fibers with different orientation and length, which gives them a relatively constant tension in flexion-extension movements.

In general, the cruciate ligaments are stretched in internal rotation and relaxed in external rotation.

The anterior cruciate ligament (figure 4) is inserted at the level of the anterior intercondylar area of the tibia, between the insertion of the anterior horn of the internal meniscus and that of the external meniscus. It extends obliquely upwards, posteriorly and laterally and is inserted at the medial part of the lateral condyle of the femur. It opposes the posterior running of the femoral condyles on the tibial plateaus during flexion and also limits hyperextension (Claes et al., 2013).

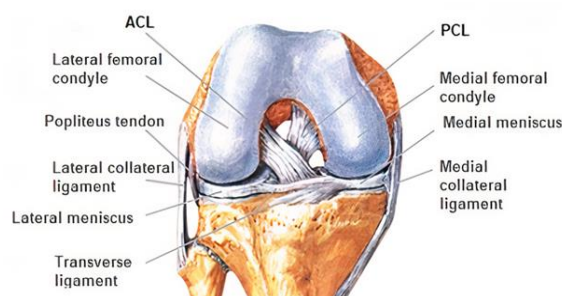


Figure 4. Anterior cruciate ligament (ACL)(source - www.micromedica.ro)

During flexion, its extension is responsible for the anterior slipping of the femoral condyle. Thus, the anterior subluxation of the tibial glenae against the femoral condyles is protected. From a clinical point of view, an anterior drawer generated by the laxity / rupture of the anterior cruciate ligament is highlighted. Because the internal collateral ligament has the same orientation as the anterior cruciate ligament (they act in synergy on the internal condyle), there is an increase in the anterior drawer during simultaneous lesions of these two ligaments (Salavati et al., 2011).

During external rotation, the LIA limits the anterior movement of the tibial plateau in the medial area, while in the internal rotational movement it limits the anterior movement of the tibial plateau in the lateral area (Lubowitz, 2012).

The anterior cruciate ligament has an elongation capacity of 20% -30%, and the mechanical strength is very important (rupture can occur at a stretch of 750 N - 2500 N).

The posterior cruciate ligament (LIP) is highlighted at the level of the posterior intercondylar area of the tibia, far behind the insertion of the posterior horns of

the medial and lateral menisci. It is oriented upwards, anteriorly and medially and is inserted on the antero-lateral side of the medial condyle of the femur (Baltaci et al., 2012).

It has a position almost vertical in flexion and horizontal in extension.

Its function is opposite to that of the anterior cruciate ligament, because it opposes the anterior sliding of the femur on the tibia, limiting the hyperflexion of the knee.

During extension, it is responsible for the posterior sliding of the condyles. Avoid posterior subluxation of the tibia relative to the femur. Breaking it causes a rear drawer to appear.

During external rotation, LIP limits the posterior displacement of the lateral tibial plateau, and during internal rotation reduces the posterior displacement of the medial tibial plateau.

The stability of the knee is complex, rotationally three-dimensional being ensured by the ligament-tendon-muscle structures (Rudolph et al. 2001).

The ligaments participate in passive stability, and the muscles and tendons in active stability.

Posterior stability of the knee joint is required in extension to avoid hyperextension, but it must also be flexible enough not to limit flexion (Guenther et al., 2015).

It is provided by:

- posterolateral angle: located behind the internal collateral ligament, composed of posterior fibers of the internal collateral ligament, the inner edge of the internal condylar fossa and the extensions of the semimembranosus muscle tendon.

- posteroexternal angle: less powerful than anterior; it is located posterior to the external collateral ligament. It consists of the lateral part of the external condylar fossa, the popliteal muscle, the arched popliteal ligament, the biceps tendon and the lateral gastrocnemius.

There are two other angles (antero-internal and antero-external), located on both sides of the patella, which further contribute to maintaining stability in rotational motion.

The ligaments contain many mechanoreceptors (Ruffini: amplitude, Pacini: speed and acceleration), and the tendons contain the Golgi apparatus and free nerve endings. Their role is mainly informative; represents the starting point of the active stability mechanisms (feedback and anticipation) that involve the muscles in protecting the knee.

A reflex arch between the anterior cruciate ligament and the hamstrings was described, which expresses their proper functioning.

Active stability is related to muscle contraction.

The hamstrings are the main protective muscles of the femur-tibial joint through their terminal inserts on both sides of the tibia.

The quadriceps is rather a stabilizer of the patella, but it also supports the collateral ligaments through its direct tendon-aponeurotic extensions and through the cruciate ligaments.

The lata fascia tensor and the femoral biceps are the external stabilizers by strengthening the external collateral ligament.

Goose leg muscles (gracilis, tailor and semitendinosus) are the medial stabilizers that support the internal collateral ligament.

The gastrocnemius, semimembranosus and popliteal muscles strengthen the capsule and are therefore posterior stabilizers.

Clinical maneuvers

At this stage of the examination it is possible to detect a bone lesion, in which case the ligaments and meniscus are not tested; the patient should benefit from additional examinations (Manske et al., 2013).

If the presumption of fracture is ruled out, the examination should be continued for ligament or meniscus injury. Clinical maneuvers are performed under conditions of optimal relaxation of the muscles that act on the knee joint. Relaxation is induced by the correct positioning of the patient. Maneuvers must always be painless. If the patient complains of pain, the clinical maneuvers lose their objective character, therefore they can be resumed only after the administration of an analgesic.

Ligament testing

1) Anterior cruciate ligament

In knee injuries, damage to the anterior cruciate ligament is much more common than that of the posterior cruciate ligament.

The Lachman test is named after orthopedic surgeon John Lachman of Temple Philadelphia School of Medicine and is the one who described it.

The Lachman test (figure 5) is a clinical test used to diagnose cruciate ligament injuries. The patient positioned in supine position, the knee flexed at 20-30 °, one hand is applied in the popliteal space, and the other on the patient's thigh (immediately above the knee), the examiner's thumb rests on the tibial tuberosity (Muller et al., 2016).

The tibia is moved anteriorly to the femur to assess the degree of movement in its anterior plane. Slight displacement of more than 2 mm suggests a possible ligament injury (weak or torn).

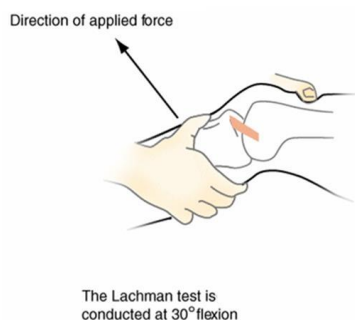


Figure 5. The Lachman test(source- www.Orthobullets.com, knee, physical, exam.com)

Pivot test. The patient is positioned in supine position, with the knee extended (figure 6). The examiner grabs the patient's leg with one hand and lifts it from the treatment table (Musahl, 2012).

Initially, perform a valgus movement, passive knee flexion at 70 ° and internal rotation. In the second stage,

progressively expand the knee, maintaining internal rotation and valgus. In the flexion movement from an amplitude of 30 ° to 40°, an interruption of movement can be observed, if the anterior cruciate ligament is broken.

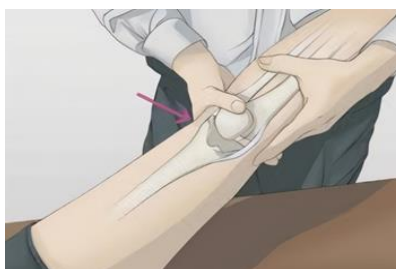

Figure 6. Pivot test(source- www.Orthobullets.com, knee, physical, exam.com)

This corresponds to the anterior subluxation of the external tibial plateau on the external femoral condyle. Compared to Lachman's test, this test is less accurate, but more specific (97%). The positivity of the test confirms the diagnosis.

Previous drawer test. The patient is positioned in supine position with the knee bent at 90 ° (figure 7). The

examiner locks the patient's leg and grabs the popliteal space with both hands, the fingers are placed along the joint line on each side of the patellar tendon. Then exert anterior traction on the leg. If the anterior cruciate ligament is broken, the translation will increase relative to the healthy knee, and the stop will be slow and progressive (Lopomo et al., 2013).

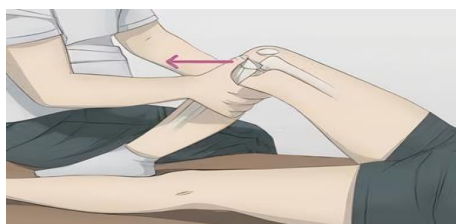

Figure 7. Previous drawer test (source- www.Orthobullets.com, knee, physical, exam.com)

This test evaluates the laxity and integrity of the anterior cruciate ligament. It can help diagnose sprains and ruptures.

2) Posterior cruciate ligament

Godfrey's sign. The patient lies in supine position. The examiner grabs the two ankles and lifts them to obtain a flexion at the hip and knee with an amplitude of 90 ° each. From this position he visualizes the anterior tuberosity of the tibia, which normally protrudes (Nelitz, 2013).

Rear drawer test. The patient lies in supine position, knee bent at 90 °. The examiner locks the patient's leg

and grabs the upper end of the tibia with both hands, and the fingers are applied to the anterior tuberosity of the tibia. Then apply pressure to the leg and push it backwards. If the posterior cruciate ligament is broken, the translation will have a higher value compared to the healthy knee, and the stop will be slow and progressive.

3) Collateral ligaments

In knee injuries, the internal collateral ligament is much more frequently injured than the external collateral ligament.

Valgus and varus test. The patient lies in supine position. To print the valgus, the examiner gently lifts

the tense lower limb and grabs the heel with one hand and the side of the knee with the other hand. Then apply pressure to the heel and inward pressure to the lower thigh. This maneuver allows testing the internal plan.

To print the varus, the examiner pulls the heel with one hand and the middle part of the knee with the other. The pressures will be inverse in relation to the valgus, respectively inside the heel and outside on the lower thigh. The maneuver tests the external plan. The presence of pain evokes, above all, a lesion of the posterolateral (valgus) or posterolateral (varus) point and expresses damage to the collateral ligament.

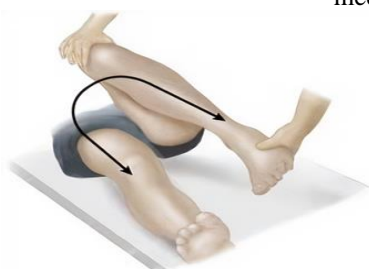

Figure 8. Mac Murray test (source- www.Orthobullets.com, knee, physical, exam.com)

To test the internal meniscus, the examiner performs an externally rotating valgus extension, and to test the external meniscus, prints an internally rotating varus extension movement.

The Apley test. The patient is positioned in a prone position, the knee bent at 90 ° (figure 9). The examiner

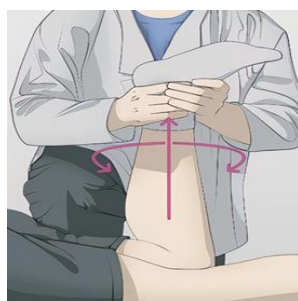


Figure 9. The Apley test (source- www.Orthobullets.com, knee, physical, exam.com)

It is possible that the test will highlight the location of the lesion due to the angle of flexion that reproduces the painful symptoms. An extension pain evokes an injury to the anterior horn. Pain that migrates posteriorly during movement between amplitudes in the range of 45 ° -120 ° creates suspicion of damage to the junction of the middle and posterior segments, while pain at an amplitude between 90 and 130 ° suggests an injury to the posterior horn.

Compression test. The patient lies in supine position. The examiner applies one hand under the heel and one on the antero-inferior part of the thigh and performs hyperextension of the knee. The onset of pain highlights the damage to the meniscus.

Issues addressed

I proposed this topic for research, because traumatology, in general, and implicitly of the knee,

These tests are then performed with a slight flexion of the knee at 20 ° to relax the anterior cruciate ligament. The examiner then applies his fingers to the joint line (external for varus, internal for valgus) to estimate the increase in interarticular space, respectively the laxity of the injured ligament.

Meniscus testing

Mac Murray test. The patient lies in supine position. The examiner lifts the patient's lower limbs and immobilizes the hip and knee (figure 8). With one hand he grabs the heel and with the other hand, in a first phase, he catches the lateral part of the knee, then the medial part at the level of the interarticular space.

grabs the patient's foot with both hands and exerts a vertical pressure on the foot, which he associates with an internal rotation to test the external meniscus, respectively with an external rotation to test the internal meniscus. Triggering pain is suggestive of meniscus damage.

covers a wide area, offering a rich and different casuistry.

Certain conditions, such as sprains, have side effects over time, and the risk of recurrence is dependent on certain factors. A ligament injury to the knee can lead to its instability and post-traumatic osteoarthritis, a minor injury is often followed by a serious injury in the next two months. An anterior trauma leads to muscle imbalances, either between the lower limbs or between the flexor and extensor muscle groups.

Conclusions

The knee, is the largest superficial joint of the human body, is less covered and protected by soft parts, but at the same time is intensely stressed both in static and locomotion, which causes more pronounced wear of its

anatomical elements, but also the predisposition to trauma.

The recommendations of specialists on the therapeutic approach to meniscus lesions and isolated lesions of the anterior cruciate ligament are convergent. However, the administration of treatment in case of a sprained knee may vary depending on the consulting physician and the patient's activity. The proposed therapeutic guidelines must be evaluated in relation to the data provided by the literature.

Meniscal lesions should be treated conservatively, if possible, to prevent intra-articular progression of the lesions.

Clinical examination is important in the correct application of treatment in the sprain of the knee. This allows, on the one hand, the elimination of the worst differential diagnoses, namely fractures, and, on the other hand, the assessment of the severity of the lesion. Primary care physicians (emergency physicians, general practitioners, and sports trauma physicians) have an important role to play in the initial therapeutic orientation. Their training in clinical examination of the knee should therefore be strengthened.

Complementary examinations are available to help the clinician establish a correct diagnosis of major and associated lesions. This is the case of ultrasound capable of assessing isolated lesions of the collateral ligaments, while MRI is the gold standard for exploring the central pivot and meniscus.

Post-traumatic pathology requires a multidisciplinary approach, both in the acute phase, but especially in the chronic phase, because only such behavior is able to reduce morbidity. At the same time, post-traumatic sequelae are constant and lead to temporary or permanent loss of functional capacity of the knee.

In this context, the preoccupations of the specialists are directed towards the knowledge of the evolution of the therapy applied in the post-traumatic pathology and the synthesis of the therapeutic approach, both from the perspective of orthopedic surgery, rheumatology and medical recovery.

References

- Ahlden M., Araujo, P., Hoshino, Y., Samuelsson, K., Middleton, K.K., Nagamune, K., 2012, Clinical grading of the pivot shift test correlates best with tibial acceleration, *Knee Surg, Sports Traumatol, Arthrosc: Off J ESSKA*, 20(4):708–712. <https://doi.org/10.1007/s00167-011-1863-8>.
- Aminaka N., Gribble, P. A., 2008. Patellar taping, patellofemoral pain syndrome, lower extremity kinematics, and dynamic postural control. *Journal of Athletic Training*, 43(1), 21e28. <https://doi.org/10.4085/1062-6050-43.1.21>.
- Ayeni O.R., 2012, Pivot shift as an outcome measure for ACL reconstruction: a systematic review, *Knee Surg Sports Traumatol Arthrosc.*, 20(4):767–777. <https://doi.org/10.1007/s00167-011-1860-y>.
- Baltacı G., Yilmaz, G., Özgür, A., 2012, The outcomes of anterior cruciate ligament reconstructed and rehabilitated knees versus healthy knees: a functional comparison, *Acta Orthop Traumatol Turc.*, 46(3):186-195. <https://doi.org/10.3944/AOTT.2012.2366>.
- Bell K.M., 2015, Novel technique for evaluation of knee function continuously through the range of flexion, *J Biomech.*, 48(13):3737–40. <https://doi.org/10.1016/j.jasej.2015.08.019>.
- Claes S., Vereecke, E., Maes, M., Victor, J., Verdonk, P., Bellemans, J., 2013, Anatomy of the anterolateral ligament of the knee, *J Anat.*, 223(4):321–328. <https://doi.org/10.1111/joa.12087>.
- Dwyer T, & Whelan D. (2012). Anatomical considerations in multiligament knee injury and surgery. *J Knee Surg.* 2012 Sep;25(4):263-74.
- Eggl S., Kohlhof, H., Zumstein, M., 2015, Dynamic intraligamentary stabilization: novel technique for preserving the ruptured ACL, *Knee Surgery, Sport Traumatol Arthrosc.*, 23(4):1215-1221. <https://doi.org/10.1007/s00167-014-2949-x>.
- Guenther D., Griffith, C., Lesniak, B., Lopomo, N., Grassi, A., Zaffagnini, S., 2015, Anterolateral rotatory instability of the knee, *Knee Surg Sports Traumatol Arthrosc.*, 23(10):2909–17. <https://doi.org/10.1007/s00167-015-3616-6>.
- Higgins L. D., Taylor, M. K., Park, D., Ghodadra, N., Marchant, M., Pietrobon, R., et al., International Knee Documentation Committee. 2007. Reliability and validity of the international knee documentation committee (IKDC) subjective knee form. *Joint, bone, spine: Revue Du Rhumatisme*, 74(6), 594e599. <https://doi.org/10.1016/j.jbspin.2007.01.036>. <https://milesallahan.com.au/>
- Ingelsrud L.H., Terwee, C.B., Gonçalves, R.S., Roos, E.M., 2014, Minimal important change for the knee injury and osteoarthritis outcome score (KOOS) in patients with knee osteoarthritis *Osteoarthr Cartil.*, 22:179-180. <https://doi.org/10.1016/j.joca.2014.02.338>.
- Kim D., Asai, S., Moon, C.W., Hwang, S.C., Lee, S., Keklikci, K., 2015, Biomechanical evaluation of anatomic single- and double-bundle anterior cruciate ligament reconstruction techniques using the quadriceps tendon, *Knee Surg Sports Traumatol Arthrosc.*, 23(3):687–95. <https://doi.org/10.1007/s00167-014-3462-y>.
- Lopomo N., Zaffagnini, S, Amis, A.A., 2013, Quantifying the pivot shift test: a systematic review, *Knee Surg Sports Traumatol Arthrosc.*, 21(4):767–83. <https://doi.org/10.1007/s00167-013-2435-x>.
- Lubowitz J.H., 2012, All-inside anterior cruciate ligament graft link: graft preparation technique, *Arthrosc Tech.*, 1(2):165-168. <https://doi.org/10.1016/j.eats.2012.06.002>.
- Manske R., Reiman, M., 2013, Functional performance testing for power and return to sports, *Sports Health*,

- 5(3):244-250.
<https://doi.org/10.1177%2F1941738113479925>.
- Muller B., Hofbauer, M., Rahneimai-Azar, A.A., Wolf, M., Araki, D., Hoshino, Y., 2016, Development of computer tablet software for clinical quantification of lateral knee compartment translation during the pivot shift test, *Comput Methods Biomech Biomed Eng.*, 19(2):217–28.
<https://doi.org/10.1080/10255842.2015.1006210>
- Musahl V., 2012, Rotatory knee laxity and the pivot shift, *Knee Surg Sports Traumatol Arthrosc.*, 20:601–602. <https://doi.org/10.1007/s00167-011-1844-y>.
- Nakamura S., Kobayashi, M., Asano, T., Arai, R., Nakagawa, Y., Nakamura, T., 2011, Image-matching technique can detect rotational and AP instabilities in chronic ACL-deficient knees, *Knee Surg, Sports Traumatol, Arthrosc: Off J ESSKA*, 19(Suppl 1):S69–76.
<https://doi.org/10.1007/s00167-011-1524-y>.
- Nelitz M., 2013, Increasing posterior tibial slope does not raise anterior cruciate ligament strain but decreases tibial rotation ability, *Clin Biomech (Bristol, Avon)*, 28(3):285–90.
<https://doi.org/10.1016/j.clinbiomech.2013.01.011>.
- Relph N., Herrington, L., Tyson, S., 2013, The effects of ACL injury on knee proprioception: a meta-analysis. *Physiotherapy*, 100(3):187-195.
<https://doi.org/10.1016/j.physio.2013.11.002>.
- Rudolph K. S., Axe, M. J., Buchanan, T. S., Scholz, J. P., Snyder-Mackler, L. 2001. Dynamic stability in the anterior cruciate ligament deficient knee. *Knee Surgery, Sports Traumatology, Arthroscopy: Official Journal of the ESSKA*, 9(2), 62e71.
<https://doi.org/10.1007/s001670000166>.
- Salavati M., Akhbari, B., Mohammadi, F., Mazaheri, M., Khorrami, M., 2011, Knee injury and Osteoarthritis Outcome Score (KOOS); reliability and validity in competitive athletes after anterior cruciate ligament reconstruction, *Osteoarthr Cartil.*, 19(4):406-410.
<https://doi.org/10.1016/j.joca.2011.01.010>.
- Suero E.M., Njoku, I.U., Voigt, M.R., Lin, J., Koenig, D., Pearle, A.D., 2013, The role of the iliotibial band during the pivot shift test, *Knee Surg, Sports Traumatol, Arthrosc: Off J ESSKA*, 21(9):2096–2100. <https://doi.org/10.1007/s00167-012-2257-2>.
- Siegel L, Vandenakker-Albanese, C., Siegel, D., 2012, Anterior Cruciate Ligament Injuries: Anatomy, Physiology, Biomechanics, and Management, *Clin J Sport Med.*, 22(4):349-355.
<https://doi.org/10.1097/JSM.0b013e3182580cd0>.
- Tardy N., Marchand, P., Kouyoumdjian, P., Blin, D., Demattei, C., Asencio, G., 2014, A preliminary in vivo assessment of anterior cruciate ligament-deficient knee kinematics with the KneeM device: a new method to assess rotatory laxity using open MRI, *Orthop J Sports Med.*, 13:2(3).
- Tourville T. W., Jarrell, K. M., Naud, S., Slauterbeck, J. R., Johnson, R. J., Beynon, B. D. 2014. Relationship between isokinetic strength and tibiofemoral joint space width changes after anterior cruciate ligament reconstruction. *The American Journal of Sports Medicine*, 42(2), 302e311.
<https://doi.org/10.1177%2F0363546513510672>.